

Subscribe | Contact Us

Compendium Of Continuing Education In Dentistry

Published by AEGIS Communications

Is Gingival Recession a Consequence of an Orthodontic Tooth Size and/or Tooth Position Discrepancy? "A Paradigm Shift"

Colin Richman, DMD


Abstract

BACKGROUND: Gingival recession (GR) is a commonly observed dental lesion. The underlying etiology has not been clearly identified, although several theories have been suggested. Tooth crowding or tooth malalignment is also frequently observed, with both conditions appearing to be more prevalent in developed countries with heterogeneous populations. **MATERIALS AND METHODS:** A total of 25 consecutively treated patients representing 72 teeth and demonstrating facial clinical GR of > 3 mm were examined clinically, photographically, and with 3-dimensional radiology using cone-beam computed tomography. All examined teeth presented with normal interproximal probing depths and attachment levels (< 4 mm). Tooth position or tooth volume plus the associated adjacent alveolar bone volume and GR were analyzed. This group was further evaluated during periodontal surgery for associated alveolar bone fenestrations or dehiscences. **RESULTS:** All teeth demonstrating > 3 mm of GR presented with significantly prominent facial tooth contours and associated alveolar bone dehiscences. Most involved teeth presented with their root structures extending beyond the facial alveolar bony housing (fenestrations). This represents a discrepancy between tooth size and alveolar bone dimensions in the buccolingual, axial, and sagittal orientation. Fewer involved teeth were malpositioned toward the buccal aspect. Both conditions were associated with facial alveolar bone dehiscences and associated GR. **CONCLUSIONS:** This study suggests tooth volume and/or tooth position within the alveolar bony housing strongly correlate with GR. All nonperiodontitis-involved teeth with GR were associated with either wider teeth or facially aligned teeth. However, it is emphasized that all facially aligned teeth, or "larger" teeth, do not necessarily present with GR. Based on these findings, the radiographic-supporting bone index is proposed. This index should facilitate appropriate evaluation of the alveolar bone supporting the mucogingival complex, both on the facial and lingual aspect of teeth. Further investigations are needed to support these preliminary data.

Gingival recession (GR) is a frequently observed clinical condition characterized by exposure of tooth cementum, predominantly on the facial surfaces of a tooth or multiple teeth. Lingual GR is observed less frequently. Clinically, GR is always accompanied by alveolar bone dehiscences. A patient may present with more than one affected tooth. The extent of GR usually directly correlates with the extent of the dehiscence observed clinically. Consequences of GR may include a patient's esthetic dissatisfaction; increased or increasing tooth sensitivity with decreasing ability of the patient and dental hygienist to effectively debride the exposed root surface; root surface decay; ongoing loss of periodontal attachment with increasing loss of periodontal tooth support; and, possibly, eventual tooth loss with potential loss of the tooth's facial bony plate.¹⁻⁶

Exposure of the root surface cementum may lead to grooving and notching of the root surface, known as noncarious cervical lesions (NCCL). The etiology of these lesions is controversial; however, recent data strongly implicate toothpaste abrasion on the exposed cemental surface of an involved tooth. Abrahamsen⁴ has described the etiology of this condition as "toothpaste abuse."⁷⁻¹⁰ Studies have reported a higher frequency of GR and grooving/notching of the exposed root surface on teeth subjected to higher levels/frequencies of toothbrushing or the use of a hard toothbrush, as well as brushing more than twice daily.¹¹⁻¹⁴ Various authors have attributed differing etiologies to the GR initiation and progression including traumatic toothbrushing habits, self-excoriation, and occlusal trauma. However, insufficient data are available to support any of these entities as a primary etiology.¹

In 2004, the average life expectancy of most Americans was 80 years;¹⁵ patients are healthier and living longer. They expect to retain their teeth or fixed tooth replacements, both in function and favorable esthetics, for life. GR may increase the risk of premature tooth loss and compromise the



Select an issue

SUBSCRIBE TODAY! 

Select a link below to view additional publications.

[Inside Dentistry](#)
[Inside Dental Assisting](#)
[Inside Dental Technology](#)
[Online Only](#)
[Special Issues +](#)
[Whitepapers](#)

ability to meet this goal.

Orthodontic crowding is defined as a "discrepancy between tooth sizes and arch length and/or tooth positioning that results in malalignment and abnormal contact relationships between teeth."¹⁶ Crowding is classified into three categories. Primary (hereditary) crowding is determined genetically and caused by disproportionately sized teeth and alveolar jaw bone housing. Secondary is an acquired anomaly caused by mesial drifting of the posterior teeth after premature loss of deciduous teeth in the lateral segment and/or lingual or distal displacement of the anterior teeth. The etiopathogenesis of tertiary crowding is still under debate and may be associated with a third molar eruption.¹⁷ This author proposes a fourth category in which alveolar bone mass is adequate and able to accommodate the tooth in three planes, but the tooth is displaced buccally. A combination of situations may also exist.

The purpose of this study was to examine the relationship between GR and the associated tooth position plus tooth volume in the buccolingual dimension, as observed by cone-beam computed tomography (CBCT).

Materials and Methods

A total of 25 consecutively treated patients referred to this author's periodontal practice for treatment of GR or periodontally accelerated osteogenic orthodontics (PAOO) therapy were evaluated. Clinical examinations included measurement of GR and attachment loss on the midfacial aspect of each involved tooth, gingival index, plaque index, and Eastman interdental bleeding index.¹⁸ GR, when present, was measured from the cemento-enamel junction (CEJ) to the gingival margin with a Colorvue® periodontal probe (Hu-Friedy, <http://www.hu-friedy.com/>). Calibrated digital photographs were obtained (Rebel XT, Canon, USA, <http://www.usa.canon.com/>; Ring Light, Canon USA; 105-mm Macro Lens, Canon USA). Three-dimensional radiographic analysis using a small-volume cone-beam scanner (Kodak Dental Systems, <http://www.kodakdental.com/>) was obtained. At the level of the interproximal and radiographically visible bone height, axial and sagittal slices of involved teeth were analyzed for radiographic root prominence and position within the associated alveolus (Figure 1 and Figure 2). Further analyses compared the radiographic data to the clinical photographic data obtained before and during surgical corrective treatment (Figure 3 and Figure 4).

Exclusion criteria included the presence of an aberrant frenum, probing pocket depth > 2 mm on the midfacial aspect of the involved tooth, and previous periodontal surgical therapy at the involved site (pocket reduction therapy or mucogingival enhancement).

Following initial patient evaluation, diagnosis, and comprehensive treatment planning, each patient was advised of all periodontal conditions present, and appropriate informed consent was obtained. Then, indicated regenerative periodontal therapy was provided. After surgical reflection of full-thickness periodontal flaps, the facial bony topography of all affected teeth was further analyzed clinically and a photographic record was obtained (Figure 4). All data were tabulated for subsequent analysis and interpretation.

Results

Each tooth demonstrating > 3 mm of facial GR also presented with a root prominence extending beyond the alveolar bony housing (dehiscence). Although all patients had previously received detailed oral hygiene instruction with a strong emphasis on interdental plaque control prior to the treatment appointment, they presented with low gingival and plaque indices at the time of surgical treatment.

Discussion

Incidence and Frequency of Gingival Recession and Orthodontic Disharmony

Epidemiologic data on 9689 American patients ages 30 to 90 years demonstrated that more than 11% have one or more tooth surfaces with > 2 mm of GR. There were 58% with 1 mm (or more) of GR. The rate of GR increased with age (an 80% prevalence of GR in patients with labially positioned teeth ages 36 to 86 compared with 40% in patients ages 16 to 25). GR occurrence is greater in men than women of the same age.^{4,19-21} The most common location of GR is the facial aspect of canines, followed successively by premolars, incisors, and molars.^{4,19-21}

A US Public Health Service report suggests 75% of American children have some degree of malocclusion. Malocclusion rates are higher in developed than in primitive countries (for instance, malocclusion is rare among Australian aborigines and Melanesian islanders) and highest in the US, perhaps because of genetic heterogeneity.²²⁻²⁴

GR may be exacerbated by:

- Root prominence in the presence of thin mucosa.
- Dehiscences or fenestrations of the underlying alveolar bone.
- Aberrant frenum activity.
- Orthodontic movement of teeth and roots outside the alveolar housing.
- Iatrogenic dental care.
- Physical trauma.
- Overzealous home care.

Pathogenesis of GR

A well-designed longitudinal clinical study of dental students demonstrated increasing GR during 5 years of close observation. GR progressed during the study period, despite detailed oral hygiene

instruction that began during the students' first year of dental school and was reinforced continually. Instruction was aimed at replacing harmful oral hygiene habits with healthier self-care techniques. Relative to this study, further research would be valuable, using CBCT to determine if adequate facial bone was initially present around the teeth demonstrating GR. Also, information regarding previous orthodontic treatment would have been helpful.

Reasons for the actual process of gingival tissue breakdown, albeit a thin and fragile biotype, need to be elucidated. Perhaps the combination of thin alveolar bone and fragile tissues, together with mechanical stress from toothbrushing, may lead to the actual loss of gingival tissue.²⁵

During orthodontic tooth movement, teeth may (inadvertently) be repositioned beyond the bony alveolar housing with resultant dehiscence and fenestration formation. These observations were seen in patients undergoing retraction of anterior teeth, monitored with lateral cephalometric radiographs and CBCT studies.²⁶ GR may be a long-term consequence of teeth moved beyond the bony housing. Generally, this occurs more frequently on the labial surfaces of canines and premolars and the mesial roots of molars. Crowding in the lower anterior segment also increases the risk of GR, probably for the same reasons.

One hypothesis regarding the etiology of recession has been proposed by Addy who suggested the buccal alveolar bone provides much of the local blood supply for buccal gingiva and loss of underlying bone is associated with eventual deficiency of gingival tissue.²⁷

Various authors define two distinct gingival phenotypes:

1. A thick phenotype characterized by a wider zone of attached tissue and a thicker facial-lingual gingival dimension. The associated teeth appear more "quadratic" and are less susceptible to recession.
2. A thinner phenotype characterized by a narrower zone of attached tissue and a thinner facial-lingual gingival dimension²⁸⁻³¹ in which the associated teeth appear to be more susceptible to gingival recession.

However, these authors do not address facial bone volume as a contributing or limiting factor to the potential risk for recession or alternatively gingival stability and, thus, adequate data are still needed to support these hypotheses.

Orthodontic Space Analysis

Orthodontists routinely compare the length of the dental arch perimeter to the mesiodistal dimension of teeth. A measurement is taken relative to the occlusal surface of all teeth in the mesiodistal dimension, and a separate measurement is made relative to the available alveolar bone perimeter length. The difference between these two measurements enables the orthodontist to evaluate the amount of space available for alignment of teeth (Figure 5 and Figure 6).^{23,24} Thus, space analysis facilitates orthodontic treatment planning, relative to tooth movement in the axial plane. In certain situations, tooth extraction may be necessary, depending on the amount of space needed to functionally and esthetically accommodate all teeth. From the periodontal perspective, however, space analysis does not evaluate the buccolingual (sagittal) dimension of the tooth or associated alveolar bone (Figure 7).

Several alternative orthodontic space evaluation indices exist, enabling the orthodontist to calculate the tooth size available alveolar bone discrepancies. However, most of these indices are associated with the mesiodistal tooth dimension only. This means the various analyses evaluate discrepancies between tooth mass and alveolar bone volume in the axial (horizontal plane) but not in the sagittal (buccolingual) dimension.³²⁻⁴²

Howe et al compared dental arch dimensions in participants demonstrating gross dental crowding with patients demonstrating little or no crowding. The researchers found no difference between the groups relative to the mesiodistal tooth dimensions. However, significant differences were observed between the skeletal arch dimensions of the two groups. Tooth mass in the crowded group exceeded available alveolar bone, suggesting the discrepancy was associated with tooth mass and alveolar bone was available to accommodate the teeth.⁴³⁻⁴⁵

Generally, GR is nonexistent in the deciduous dentition because deciduous teeth have less volume in three planes of orientation, especially the sagittal plane.

If there is a moderate mesiodistal space discrepancy not requiring tooth extraction, expansion of the arch becomes a preferred treatment option. The potential consequence of the buccal movement of teeth is that the teeth may be displaced further buccally and out of the supporting alveolar bone, exacerbating a potential mucogingival problem.^{26,46} This assumes 3-dimensional orthodontic movement and a buccolingual quantitative tooth-size available bone-mass discrepancy.

Other authors advocate mesiodistal stripping of teeth to treat a moderate space discrepancy. From a periodontal perspective, this technique does not accommodate the potential discrepancy between tooth width and associated alveolar bone width (in the buccolingual dimension). This treatment also might cause long-term interproximal root proximity problems and associated periodontal consequences.⁴⁷⁻⁴⁹

As of this writing, this author is not aware of clinically relevant diagnostic tools enabling effective calculation of the third dimension of an orthodontic crowding discrepancy, namely the amount of available alveolar bone, as well as tooth width size in the buccolingual (sagittal) dimension. Such a diagnostic tool would help identify potential risk patterns during orthodontic treatment. Figure 8, Figure 9 and Figure 10 demonstrate a clinical situation in which the buccolingual bone width exceeds the buccolingual tooth width, providing the entire periphery of the tooth root with adequate

supporting bone 2 mm apical to the CEJ. This bone will effectively support soft tissue at the appropriate level, relative to the CEJ.

Conversely, Figure 1, Figure 2 and Figure 3 demonstrate a situation in which part of the facial aspect of the tooth is outside the buccal housing of the bone. Significant GR is noted with this facial alveolar bone discrepancy. Currently, the increasing use of CBCT, as well as 3-dimensional imaging, is facilitating the accuracy of tooth and bone volumetric assessment.

Through the use of CBCT and clinical photography, this author has observed a consistent relationship between GR and the deficient buccolingual dimensions of the associated alveolar bone at the coronal third of the tooth's root. Based on these observations, a new radiography-based index the radiographic supporting bone index (RSBI) is proposed. This index is based on the difference between the alveolar bone width, measured at a position 2 mm to 3 mm from the CEJ (in the midfacial buccolingual dimension), and the same width of the tooth. Then, the two measurements are subtracted. The values are obtained from a CBCT study of the patient and essentially used to compare the tooth width at this predefined position with the available bone width at the same position.

The proposed categories of RSBI are:

Class A RSBI represents the ideal clinical situation: 1.5 mm to 2 mm of available supporting bone on the facial or lingual aspect of each tooth.^{50,51}

Class B RSBI represents a compromised but potentially stable situation: < 1.5 mm but > 0.5 mm of available supporting facial or lingual alveolar bone.

Class C RSBI represents a high-risk situation for future GR \geq 0.5 mm of available bone at the measured sites. This category becomes relevant if buccal orthodontic tooth movement is indicated for the specific tooth. The same analysis applies to the lingual aspect of the tooth if lingual orthodontic tooth movement is anticipated.

Figure 11, Figure 12, Figure 13 and Figure 14 represent Class A RSBI on the lingual aspects of teeth Nos. 10 to 12. The facial aspect of tooth No. 12 represents a Class B RSBI (Figure 13). Note the adequate soft-tissue support at the CEJ on the facial aspect. Observe the apical displacement of facial bone seen in the surgical slide.

Teeth Nos. 10 and 11 represent Class C RSBI on the facial aspect, but note apical displacement of facial bone seen in the surgical slide. Figure 15 demonstrates Class B RSBI for tooth No. 25 and Class C RSBI for teeth Nos. 22 to 24 and 27.

Thus, RSBI may be a useful risk assessment tool for predicting potential GR when dental therapy is indicated, including:

- tooth removal with subsequent implant placement.
- orthodontic treatment.
- esthetic restorative dental therapy.

This author understands that numerous clinical nonorthodontic situations involve < 1.5-mm RSBI with stable mucogingival complexes that do not demonstrate GR or potential future GR. The value of this proposed index may be associated with treatment planning decisions, relative to orthodontic expansion and tooth extractions with proposed implant replacement in the esthetic zone. Further research is needed to elucidate the ideal volume of bone around the periphery of each tooth that is required to support the mucogingival complex throughout dental and orthodontic treatment procedures (Figure 15).

Additional clinical observation suggests patients with alveolar bone dehiscences are at greater risk of clinically significant future GR than patients with adequate supporting bone close to the CEJ. A dehiscence is described as "the absence of alveolar cortical plate sometimes exceeding more than half of the root length and often resulting in a denuded root surface"⁵²⁻⁵⁴ (Figure 16).

In this situation, if during orthodontic tooth movement the teeth are translated further labially, then treatment might exacerbate the risk of GR. It is also noted that GR is rare in cases of fenestration with adequate bone at the CEJ-supporting gingival tissue. A fenestration is described as a window-like aperture or opening found in the alveolar bone over the tooth root and exposes the facial or lingual root surface⁵²⁻⁵⁴ (Figure 16, Figure 17 and Figure 18).

Figure 19 demonstrates ideal facial bone and virtually no risk for GR following orthodontic expansion in the buccal direction.

Periodontally Accelerated Osteogenic Orthodontics

The emerging treatment protocol of PAOO, as proposed by Wilcko et al, meets the objective of "alveolar thickening" at potential risk sites by augmenting the horizontal dimension of the alveolar bone, with both hard- and soft-tissue grafting agents, prior to the initiation of orthodontic treatment.⁵⁵

Selected Tooth Extractions as Part of Orthodontic Treatment

Whether tooth extraction influences root resorption is controversial. Higher root resorption rates have been found in patients receiving treatment with tooth extractions than in those who did not have extractions.^{56,57} Also, the duration of orthodontic treatment with fixed orthodontic appliances has been found to contribute to the degree of root resorption. Average treatment length for patients without root resorption is 1.5 years, and for patients with severe root resorption 2.3 years.⁵⁸ Preliminary data from this author's ongoing unpublished office-based studies suggest that more than

75% of patients who have received bicuspid tooth extractions with associated orthodontic therapy demonstrate clinically significant GR at one or more tooth sites. Therefore, it is assumed that the original orthodontic diagnosis, necessitating tooth extractions to gain space for tooth alignment, was predicated on a significant tooth-size alveolar bone discrepancy, in which the tooth volume significantly exceeded the alveolar bone volume in the horizontal (axial) plane and probably in the sagittal plane, as well. The sagittal plane discrepancy is likely associated with a deficient quantity of facial alveolar bone and thus increased risk for short- or long-term GR.

Conclusions

A RSBI of 1.5 mm to 2.0 mm in the natural dentition is seemingly required to maintain a stable mucogingival complex and minimize GR. This author recognizes that the preceding concepts are based on clinical observation and that substantial further research and interpretation is needed to support this hypothesis.

Reidel stated: "...from an applied as well as stability perspective orthodontic expansion in the mandibular arch, in a patient with thin gingival tissue should be avoided, if possible." He further stated that, "...if frontal expansion is still performed in association with orthodontic therapy, the buccolingual thickness of the hard and soft tissues should be evaluated." If surgical intervention is considered necessary to reduce the risk of soft-tissue recessions, the goal should be increasing the thickness of the covering tissues (eg, grafts) and not the apico-coronal width of the gingival tissues.⁵⁶

About the Author

Colin Richman, DMD
Assistant Clinical Professor
Medical College of Georgia
Augusta, Georgia
Private Practice,
Roswell, Georgia

American Board of Periodontology

References

1. Baker DL, Seymour GJ. The possible pathogenesis of gingival recession. A histological study of induced recession in the rat. *J Clin Periodontol.* 1976;3(4):208-219.
2. Løe H, Anerud A, Boysen H. The natural history of periodontal disease in man: prevalence, severity, and extent of gingival recession. *J Periodontol.* 1992;63(6):489-495.
3. Susin C, Hass AN, Oppermann RV, et al. Gingival recession: epidemiology and risk indicators in a representative urban Brazilian population. *J Periodontol.* 2004; 75(10):1377-1386.
4. Tugnait A, Clerehugh V. Gingival recession—its significance and management. *J Dent.* 2001;29(6):381-394.
5. Bernimoulin J, Curilović Z. Gingival recession and tooth mobility. *J Clin Periodontol.* 1977;4(2):107-114.
6. Wennström JL. Mucogingival therapy. *Ann Periodontol.* 1996;1(1):671-701.
7. Abrahamsen TC. The worn dentition—pathognomonic patterns of abrasion and erosion. *Int Dent J.* 2005;55(4 suppl 1):268-276.
8. Dzakovich JJ, Oslak RR., In vitro reproduction of non-carious cervical lesions. *J Prosthet Dent.* 2008;100(1):1-10.
9. Miller WD. Experiments and observations on the wasting of tooth tissue variously designated as erosion, abrasion, chemical abrasion, denudation, etc. *Dent Cosmos.* 1907; XLIX:1-23;109- 124;225-247.
10. Imfeld T. Dental erosion. Definition, classification and links. *Eur J Oral Sc.* 1996;104;2(Pt 2):151-155.
11. Sagnes A, Gjermo P. Prevalence of oral soft and hard tissue lesions related to mechanical tooth cleansing procedures. *Community Dent Oral Epidemiol.* 1976;4(2):77-83.
12. Khocht A, Simon G, Person P, et al. Gingival recession in relation to history of hard toothbrush use. *J Periodontol.* 1993;64(9): 900-905.
13. Rajapakse PS, McCracken GI, Gwynnett E, et al. Does tooth brushing influence the development and progression of non-inflammatory gingival recession? A systematic review. *J Clin Periodontol.* 2007;34(12):1046-1061.
14. McCracken GI, Heasman L, Stacey F, et al. The impact of powered and manual toothbrushing on incipient gingival recession. *J Clin. Periodontol.* 2009;36(11):950-957.
15. National Center for Health Statistics, Health, United States, 2004, with Chartbook on Trends in the Health of Americans, Hyattsville, MD: 2007.
16. American Academy of Periodontology. *Glossary of Periodontal Term.* 4th ed. Chicago, IL: American Academy of Periodontology; 2001:P11.
17. Daskalogiannakis J, McNarma JA, Van der Linden FP, et al, eds. *Glossary of Orthodontic Terms.* Hanover Park, IL: Quintessence Publishing Co; 2000:35.

18. Caton JG, Polson AM. The interdental bleeding index: a simplified procedure for monitoring gingival health. *Compend Contin Educ Den*. 1985;6(2):88,90-92.
19. Albandar JM, Kingman A. Gingival recession, gingival bleeding, and dental calculus in adults 30 years of age and older in the United States, 1988-1994. *J Periodontol*. 1999;70(1):30-43.
20. Vehkalahti M. Occurrence of gingival recession in adults. *J Periodontol*. 1989;60(11):599-603.
21. Orchardson R, Collins WJ. Clinical features of hypersensitive teeth. *Br Dent J*. 1987;162(7):253-256.
22. Zwemer JD, Young WD. Summary of studies on the prevalence of malocclusion. In: Proffit WR, Norton LA, eds. *Education for Orthodontics in General Practice*. Lexington, KY: University of Kentucky Department of Orthodontics; 1966: P102-P110.
23. Proffit WR, Fields HW Jr, Moray LJ. Prevalence of malocclusion and orthodontic treatment needs in the United States: estimates from the NHANES III survey. *Int J Adult Orthodon Orthognath Surg*. 1998;13(2):97-106.
24. Kelly JE, Sanchez M, Van Kirk LE. An Assessment of the Occlusion of Teeth in Children. Data from the National Health Survey. National Center for Health Statistics Centers for Disease Control and Prevention. Atlanta, GA. DHEW Publication No. (HRA) 1973:74-1612.
25. Daprile G, Gatto MR, Checchi L. The evolution of buccal gingival recessions in a student population: a 5-year follow-up. *J Periodontol*. 2007;78(4):611-614.
26. Sarikaya S, Haydar B, Cığır S, et al. Changes in alveolar bone thickness due to retraction of anterior teeth. *Am J Orthod Dentofacial Orthop*. 2002;122(1):15-26.
27. Addy M. Dentine hypersensitivity: definition, prevalence, distribution and etiology. In: Addy M, Embery G, Edgar WM, et al, eds. *Tooth Wear and Sensitivity: Clinical Advances in Restorative Dentistry*. London, UK: Martin Dunitz; 2000:239-238.
28. Müller HP, Eger T. Gingival phenotypes in young male adults. *J Clin Periodontol*. 1997;24(1):65-71.
29. Müller HP, Heinecke A, Schaller N, et al. Masticatory mucosa in subjects with different periodontal phenotypes. *J Clin Periodontol*. 2000;27(9):621-626.
30. Olsson M, Lindhe J. Periodontal characteristics in individuals with varying form of the upper central incisors. *J Clin Periodontol*. 1991;18(1):78-82.
31. Müller HP, Eger T. Masticatory mucosa and periodontal phenotype: a review. *Int J Periodontics Restorative Dent*. 2002;22(2):172-183.
32. Nance HN. The limitation of orthodontic treatment. I. Mixed dentition diagnosis and treatment. *Am J Orthod*. 1947;33: 177-223.
33. Nance HN. The limitation of orthodontic treatment. II. Diagnosis and treatment in the permanent dentition. *Am J Orthod*. 1947;33:253-301.
34. Hunter WS. Application of analysis of crowding and spacing of the teeth. *Dent Clin North Am*. 1978;22(4):563-577.
35. Moyers RE. *Handbook of Orthodontics*. 3rd ed. Chicago, IL: Year Book Medical Publishers, Inc; 193.
36. Tanaka MM, Johnston LE. The prediction of the size of unerupted canines and premolars in a contemporary orthodontic population. *J Am Dent Assoc*. 1974;88(4):798-801.
37. Staley RN, Kerber PE. A revision of the Hixon and Oldfather mixed-dentition prediction method. *Am J Orthod*. 1980;78(3):296-302.
38. Bolton WA. The clinical application of a tooth-size analysis. *Am J Orthod*. 1962;48:504-529.
39. Hixon EH, Oldfather RE. Estimation of the sizes of unerupted cuspid and bicuspid teeth. *Angle Orthod*. 1958;28:236-240.
40. Shigenobu N, Hisano M, Shima S, et al. Patterns of dental crowding in the lower arch and contributing factors. A statistical study. *Angle Orthod*. 2007;77(2):303-310.
41. Puri N, Pradhan KL, Chandna A, et al. Biometric study of tooth size in normal, crowded, and spaced permanent dentitions. *Am J Orthod Dentofacial Orthop*. 2007;132(3)3:279.e7-e14.
42. Staley RN, O'Gorman TW, Hoag JF, et al. Prediction of the widths of unerupted canines and premolars. *J Am Dent Assoc*. 1984;108 (2):185-190.
43. Howe RP, McNamara JA Jr, O'Connor KA. An examination of dental crowding and its relationship to tooth size and arch dimension. *Am J Orthod*. 1983;83(5):363-373.
44. Bernabé E, Flores-Mir C. Dental morphology and crowding. A multivariate approach. *Angle Orthod*. 2006;76(1):20-225.
45. Lestrel PE, Takahashi O, Kanazawa E, et al. A quantitative approach for measuring crowding in the dental arch: fourier descriptors. *Am J Orthod Dentofacial Orthop*. 2004;125(6):716-725.

46. Fuhrmann R. Three-Dimensional evaluation of periodontal remodeling during orthodontic treatment. *Seminars in Orthodontics*. 2002;8(1):23-28.
47. Peck H, Peck S. An index for assessing tooth shape deviations as applied to the mandibular incisors. *Am J Orthod*. 1972; 61(4):384-401.
48. Bernabé E, Flores-Mir C. Are the lower incisors the best predictors for the unerupted canine and premolars sums? An analysis of a Peruvian sample. *Angle Orthod*. 2005;75(2):202-207.
49. Shah AA, Elcock C, Brook AH. Incisor crown shape and crowding. *Am J Orthod Dentofacial Orthop*. 2003;123(5):562-567.
50. Katranji A, Misch K, Wang HL. Cortical bone thickness in dentate and edentulous human cadavers. *J Periodontol*. 2007;78(5):874-878.
51. Fickl S, Zuhr O, Wachtel H, et al. Hard tissue alterations after socket preservation: an experimental study in the beagle dog. *Clin Oral Implants Res*. 2008;19(11):1111-1118.
52. Elliott JR, Bowers GM. Alveolar dehiscence and fenestrations. *Periodontics*. 1963;1:245-248.
53. Larato DC. Alveolar plate fenestrations and dehiscences of the human skull. *Oral Surg Oral Med Oral Pathol*. 1970;29(6):816-819.
54. Rupprecht RD, Horning GM, Nicoll BK, et al. Prevalence of dehiscences and fenestrations in modern American skulls. *J Periodontol*. 2001;72(6):722-729.
55. Wilcko WM, Wilcko T, Bouquot JE, et al. Rapid orthodontics with alveolar reshaping: two case reports of decrowding. *Int J Periodontics Restorative Dent*. 2001;21(1):9-19.
56. Riedel RA. A post-retention assessment of relapse, recidivism, adjustment, change and stability. In: Moorrees CFA, van der Linden FPGM, eds. *Orthodontics: Evaluation and Future. Proceedings of the International Conference on the Occasion of the 25th Anniversary of the Orthodontic Department of the University of Nymegen, The Netherlands*. 1988; 22-24:281-306.
57. Travess H, Roberts-Harry D, Sandy J. Orthodontics. Part 6: risks in orthodontic treatment. *Br Dent J*. 2004;196(2):71-77.
58. Apajalahti S, Peltola JS. Apical root resorption after orthodontic treatment—a retrospective study. *Eur J Orthod*. 2007;29(4):408-412.

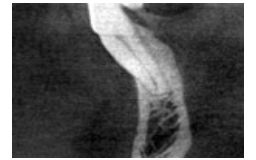


Figure 1

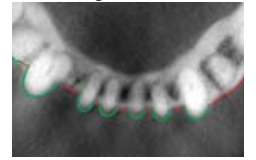

Figure 2

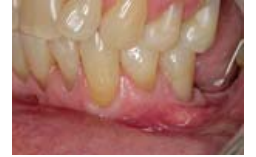

Figure 3

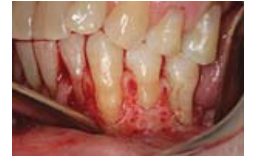

Figure 4

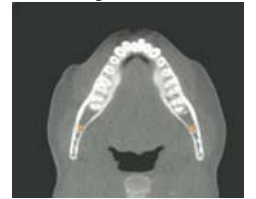


Figure 5

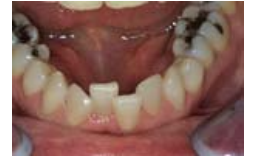

Figure 6

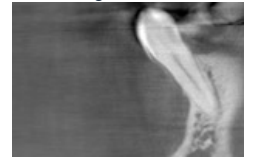

Figure 7

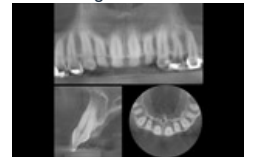


Figure 8

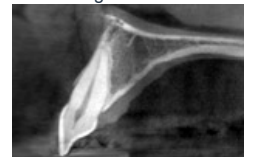


Figure 9

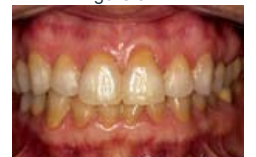

Figure 10



[BACK TO TOP](#)

© 2011 AEGIS Communications | [Contact Us](#) | [Terms of Service](#) | [Privacy Statement](#)