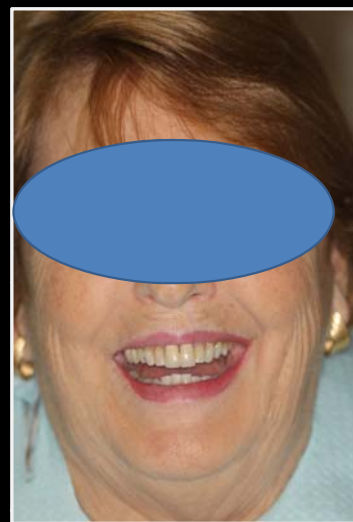
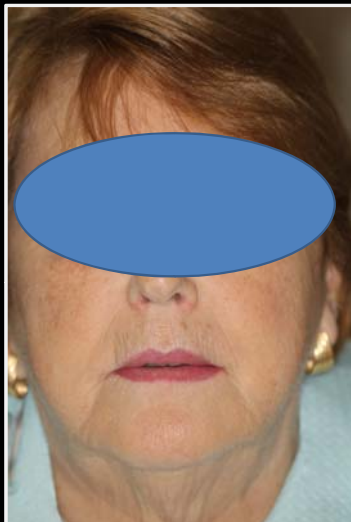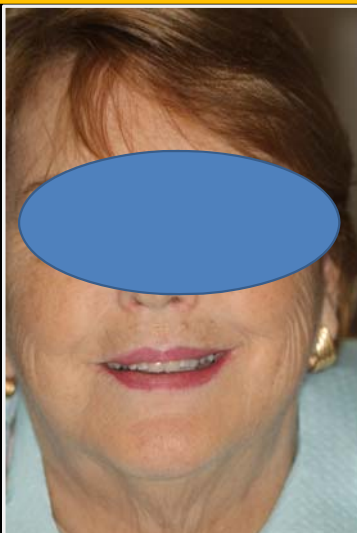


### Introduction-Background

- Chief Dental Complaint: Shifting mandibular anterior teeth.\
- Left side TMJ symptoms
- Reason for Initial GD Visit: As above
- Oral Image and Expectation: Wants whiter teeth, but loves her two anterior crowns, 27 years old. Unsure of potential of dental care, and unsure of her specific expectations. Would like to retain all natural teeth for life.
- Concern that a conventional restoration placed 5 years ago was in hyper-occlusion, causing shifting, crowding and TMJ symptoms.
- Wants missing posterior teeth replaced

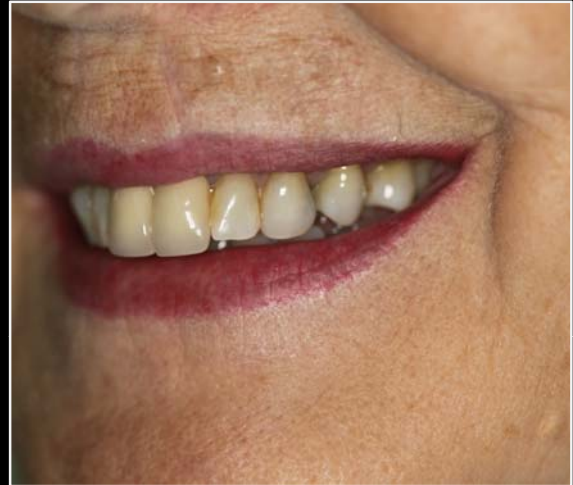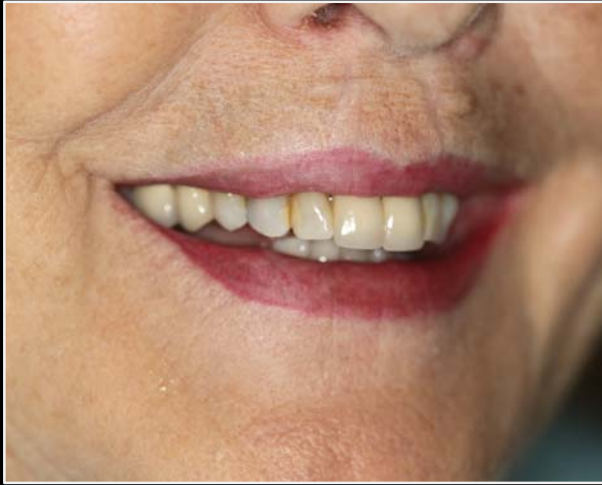[www.sscofatlanta.com](http://www.sscofatlanta.com)

### Extra-Oral (Rest, smile, laugh)



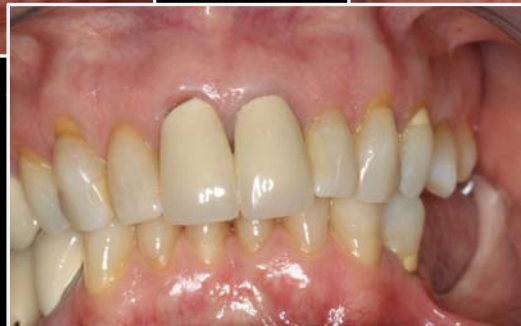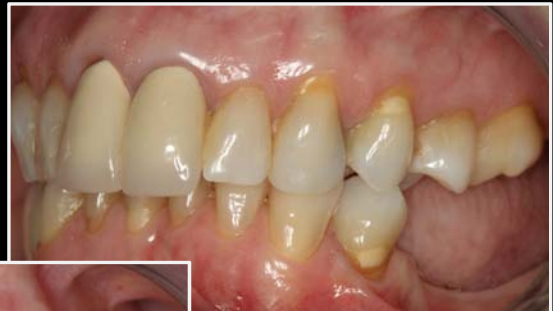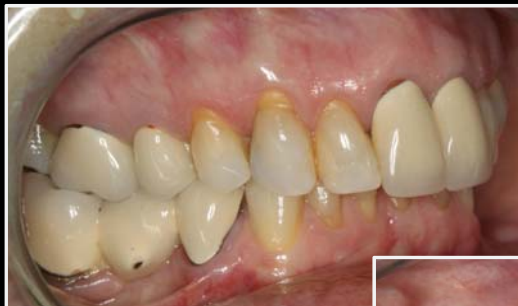om

## Extra oral, buccal corridors



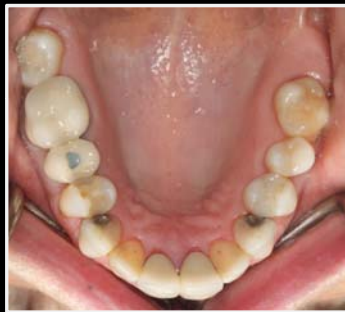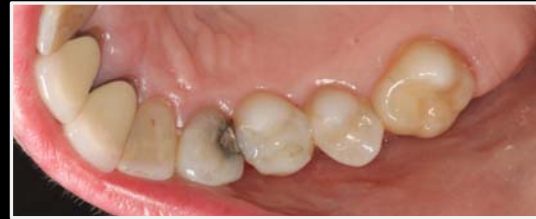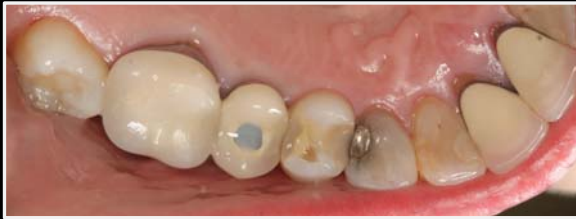[www.sscofatlanta.com](http://www.sscofatlanta.com)

## Periodontal: GI/PI/Recession/Frena/Other



[www.sscofatlanta.com](http://www.sscofatlanta.com)

## Periodontal Images - Lingual



[www.sscofatlanta.com](http://www.sscofatlanta.com)

	1	2	3	4	5	6	7	8	9	10	11	12	13	14	15	16
F																
PD																
GM																
CAL	3	2	3													
MGJ																
FG																
Bld																
Sup																
Sup																
Bld																
FG																
MGJ																
CAL	2	3	4													
GM																
PD																
L																
PMB																
PMB																
L																
PD																
GM																
CAL																
MGJ																
FG																
Bld																
Sup																
Sup																
Bld																
FG																
MGJ																
CAL																
GM																
PD																
F																
	32	31	30	29	28	27	26	25	24	23	22	21	20	19	18	17

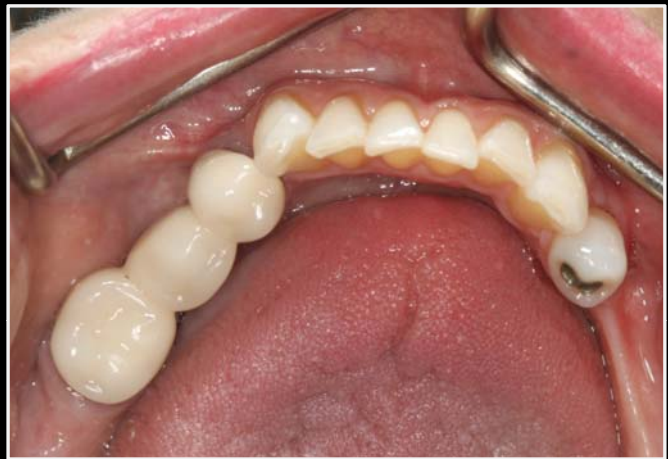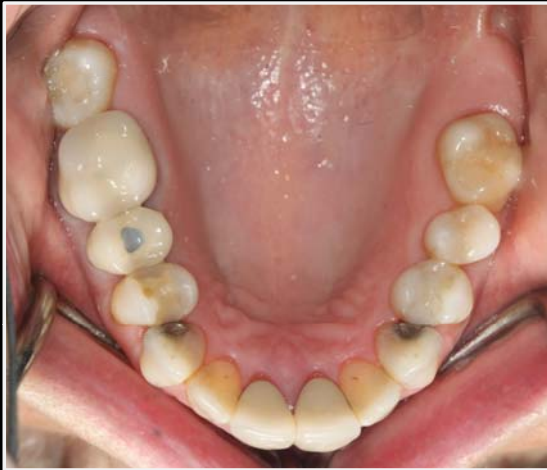## Periodontal charting

[www.sscofatlanta.com](http://www.sscofatlanta.com)

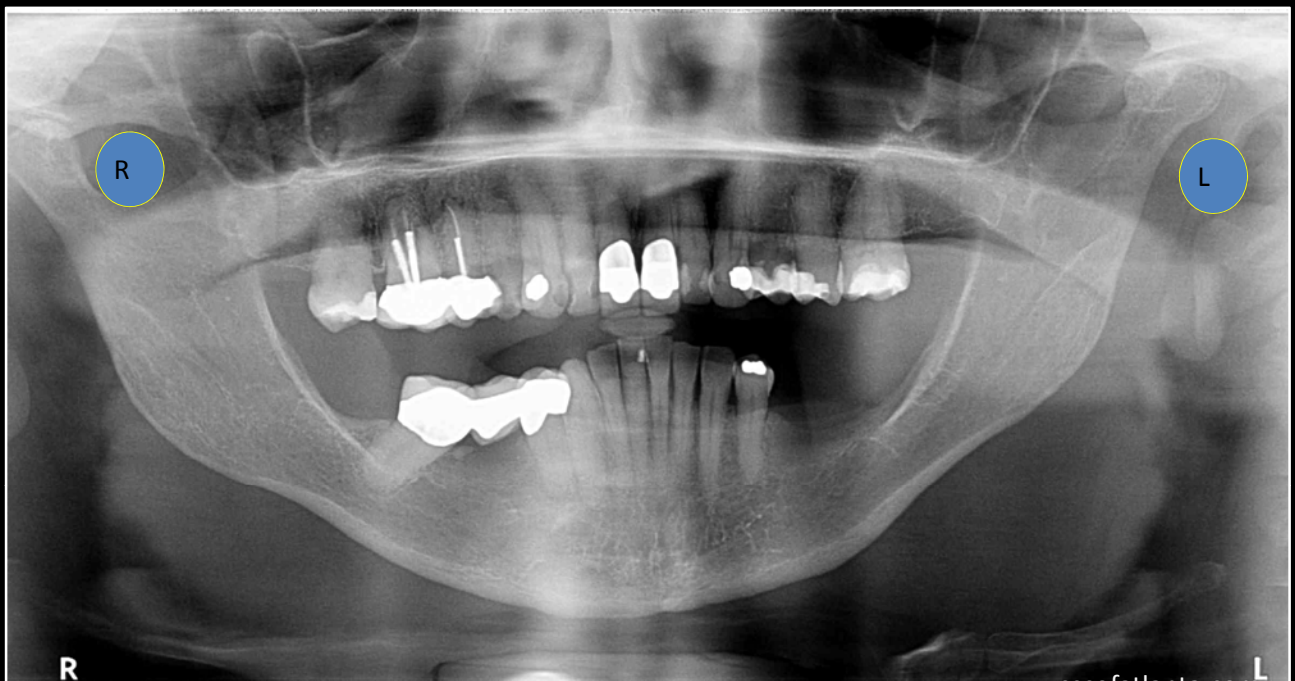L

## Occlusal views

R



[www.sscofatlanta.com](http://www.sscofatlanta.com)



[www.sscofatlanta.com](http://www.sscofatlanta.com)