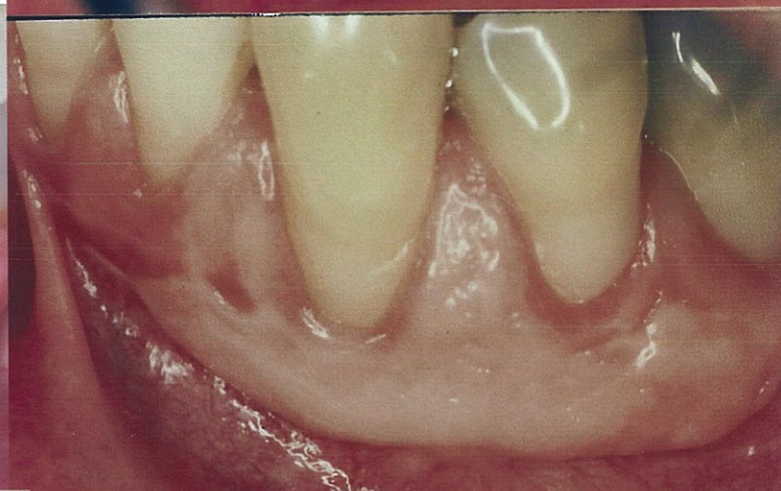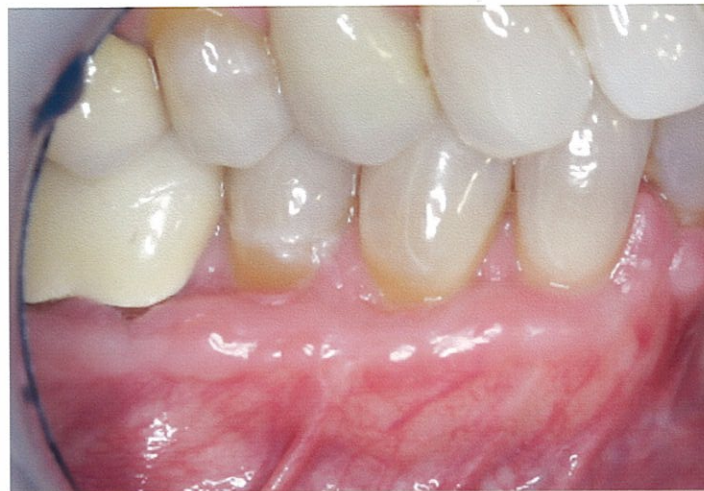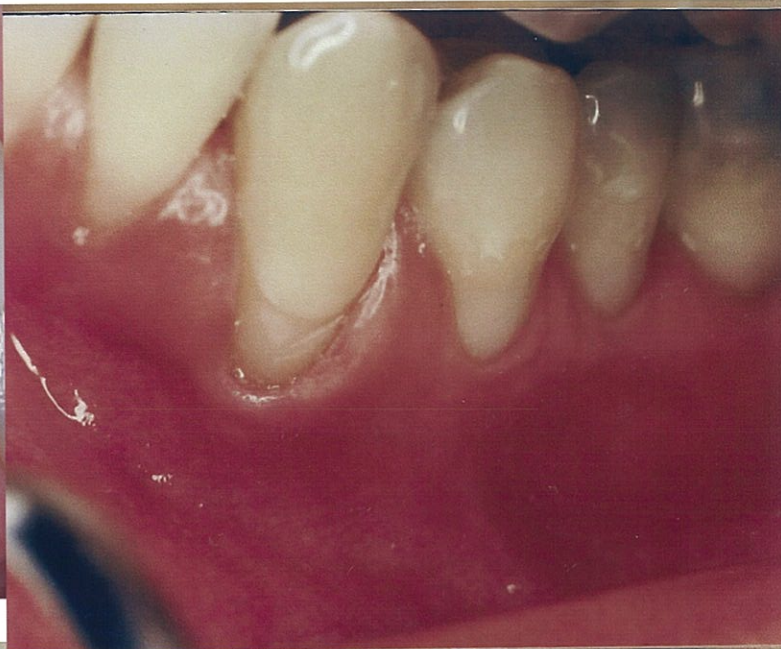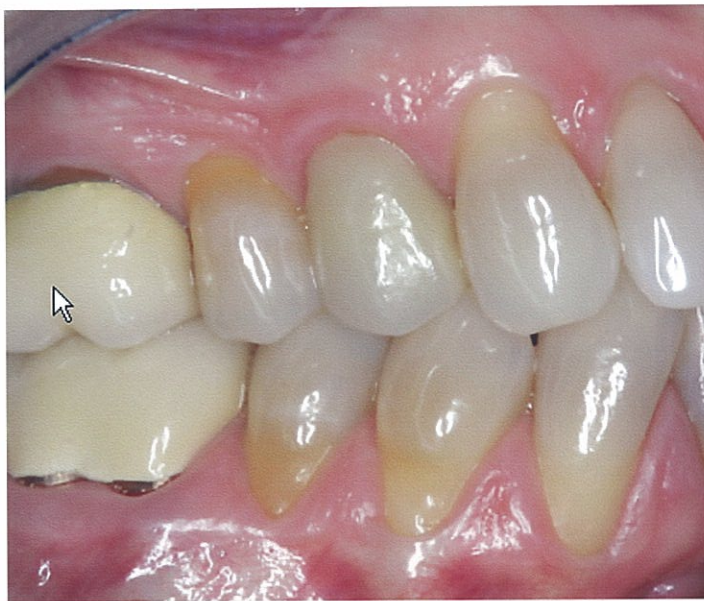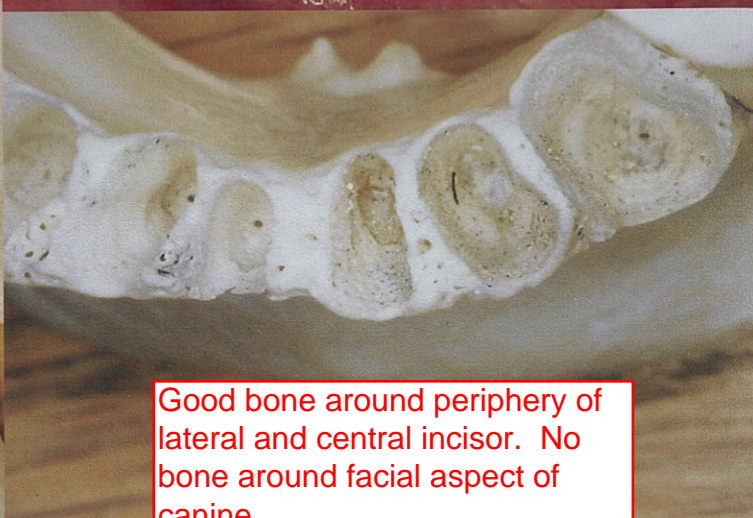


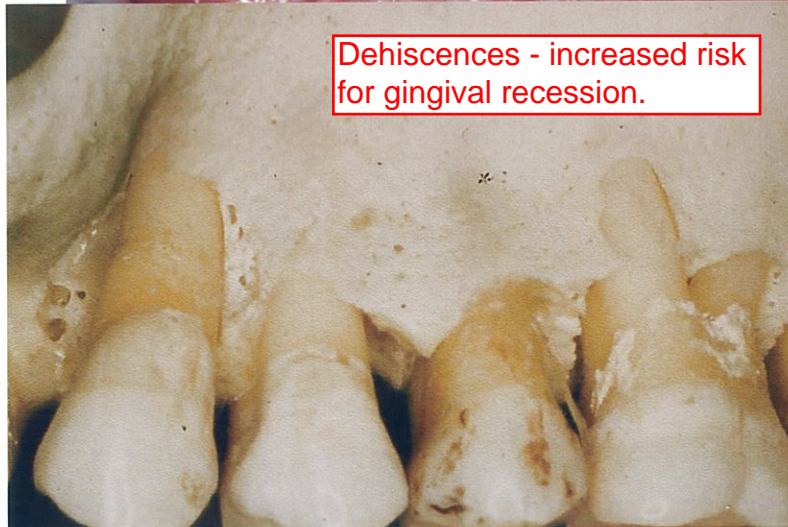Gingival Graft—Basic

Left side: Connective tissue gingival inlay graft - currently used.
Right side: Obsolete gingival onlay graft - no longer used.

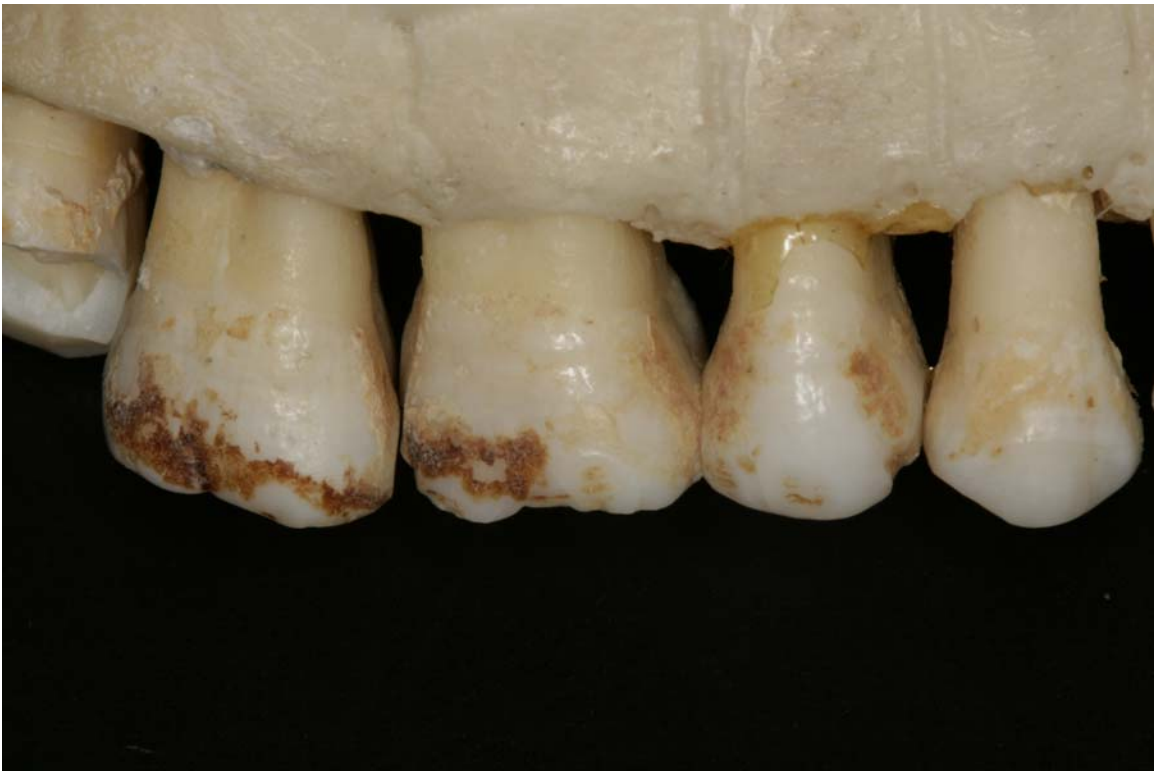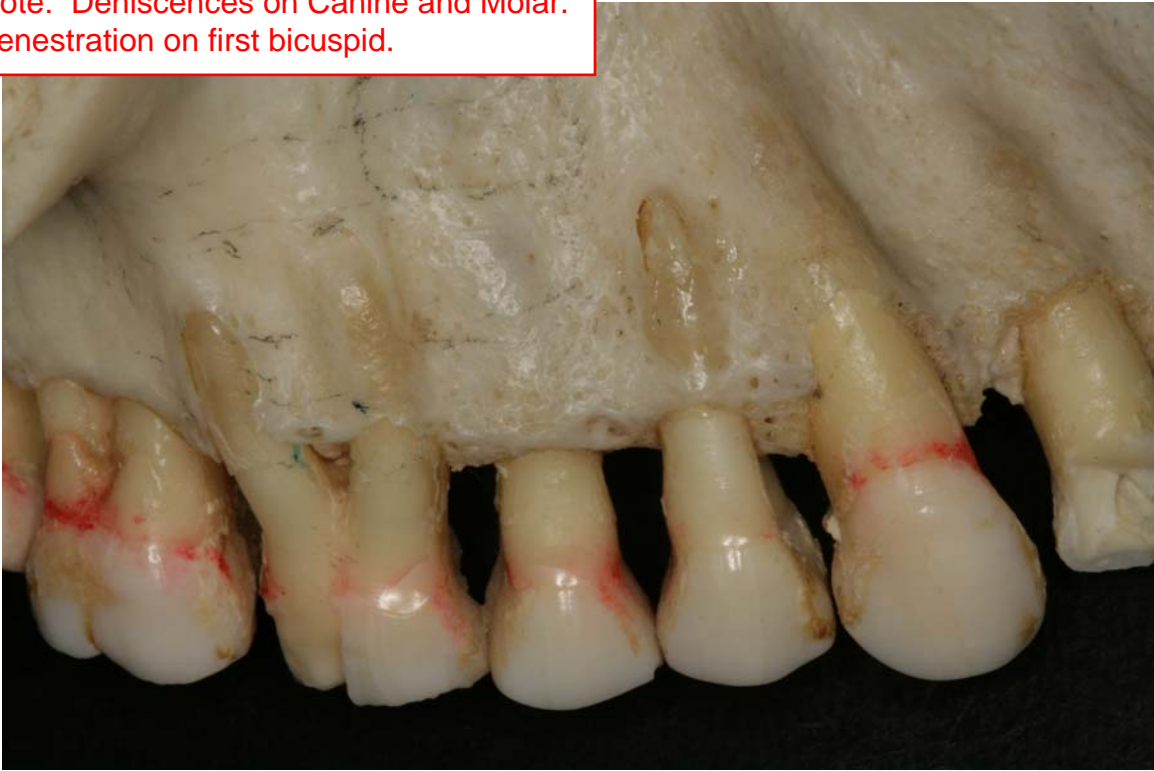


Dehiscences - increased risk for gingival recession.



Good bone around periphery of lateral and central incisor. No bone around facial aspect of canine.

Note: Dehiscences on Canine and Molar.
Fenestration on first bicuspid.



Note: Fenestrations and dehiscences on the skeletal images.
Soft tissue 'gum/gingiva' needs underlying bone to retain it's integrity.